

# Efficacy of Digital Volume Tomography in the Preoperative Assessment of Position of Inferior Alveolar Canal with Impacted Mandibular Third Molars in a Subset of Indian Population

Biyas Bhowmik, Venkatesh G. Naikmasur<sup>1</sup>, Kruthika Satyabodh Guttal<sup>1</sup>

Department of Oral Medicine and Radiology, Haldia Institute of Dental Sciences and Research, Haldia, West Bengal, <sup>1</sup>Department of Oral Medicine and Radiology, SDM College of Dental Sciences and Hospital, Dharwad, Karnataka, India

## Abstract

**Context:** Choosing an imaging source, which provides minimum radiation exposure to the patient, to facilitate surgical removal of impacted mandibular third molars (MTMs), thereby avoiding unwanted neurological complications. **Aim:** The aim of the study was to assess the efficacy of digital volume tomography (DVT) in evaluating the position of inferior alveolar canal (IAC) in relation to impacted MTMs and comparing it with conventional radiography (CR) in a subset of the Indian population. **Materials and Methods:** Four experienced observers assessed two groups: 33 DVT and 33 CR images, for the position of root-tips of impacted MTM in the proximity to IAC, in both vertical and horizontal planes. The diagnostic information was compared in both the groups. **Statistical Analysis:** Chi-square test, Mann-Whitney U-test, and Kappa statistics were used. **Results:** Comparison between DVT and CR revealed no statistically significant variation in assessing relationship in the vertical plane. There was, however, a significant difference between the groups, while comparing the diagnostic information for the horizontal dimension, for both the mesial and the distal roots, with an advantage for DVT ( $P < 0.05$  for both mesial and distal roots). **Conclusion:** DVT is highly accurate in predicting neurovascular bundle exposure. It is indispensable for preoperative evaluation of impacted MTM.

**Keywords:** Conventional radiography, digital volume tomography, impacted mandibular third molars, inferior alveolar canal

## INTRODUCTION

Removal of impacted mandibular third molars (MTMs) is one of the most common surgical procedures, commonly encountered reasons being: (a) pericoronitis (accompanied by symptoms of pain, abscess, or osteomyelitis), (b) dental caries, and (c) root resorption of mandibular second molars.<sup>[1,2]</sup> The impacted MTMs have an intimate relationship with the inferior alveolar neurovascular bundle, as seen in conventional radiography (CR) such as intraoral periapical radiograph (PR) and/or panoramic radiography orthopantomograph (OPG).<sup>[3]</sup> If the root-tips (RTs) are at level or inferior to the inferior alveolar canal (IAC), an additional radiologic imaging in a second plane is essential to identify the position of the RT buccal, inferior, or lingual to the nerve.

One of the conventional techniques used clinically, for the localization of the mandibular canal lingual, buccal, or below an impacted MTM, is a modification of the “Tube-Shift” method (PR and vertical parallax) as suggested by Frank and first

described by Richards.<sup>[4,5]</sup> In the mouth, two PRs are performed at 0° and -25° vertical angulation. PR taken from -25° below the plane of occlusion will make a distant object move downward in relation to an object in the foreground; that is, if the mandibular canal lies lingual to the impaction, it will move downward in relation to the roots of the impacted MTM. Conversely, a canal on the buccal side of the roots will appear to move upward on the roots. If the canal remains in the same position, it is directly below the roots, or passes in between the roots, or is in a groove in relation to the root substance.

Another technique is the symmetrical PA cephalometric radiograph occlusal plane angle (OPA) with wide open mouth

**Address for correspondence:** Dr. Biyas Bhowmik,  
Department of Oral Medicine and Radiology, Haldia Institute of Dental  
Sciences and Research, Balughata, Haldia - 721 645, West Bengal, India.  
E-mail: [biyasbhowmik@gmail.com](mailto:biyasbhowmik@gmail.com)

This is an open access journal, and articles are distributed under the terms of the Creative Commons Attribution-NonCommercial-ShareAlike 4.0 License, which allows others to remix, tweak, and build upon the work non-commercially, as long as appropriate credit is given and the new creations are licensed under the identical terms.

**For reprints contact:** [reprints@medknow.com](mailto:reprints@medknow.com)

**How to cite this article:** Bhowmik B, Naikmasur VG, Guttal KS. Efficacy of digital volume tomography in the preoperative assessment of position of inferior alveolar canal with impacted mandibular third molars in a subset of Indian population. Indian J Dent Sci 2018;10:153-9.

and 15° angulation.<sup>[1]</sup> However, the need of the hour is an imaging technique, which is cost-effective, provides accurate details, preferably three dimensional (3D), with low radiation dosage.

Digital volume tomography (DVT) is a recent technology which uses a divergent, “cone-shaped” source of ionizing radiation along a circular trajectory, and a two-dimensional area detector fixed on a rotating gantry to acquire multiple sequential projection images in one complete scan around the area of interest. Advantages of such a system include reduced cost, excellent submillimeter resolution, shorter examination time, reduced image distortion due to internal patient movements, and increased X-ray tube efficiency.<sup>[6]</sup>

### Aims and objectives

The aim and objective of the study were to assess and compare the relationship of impacted MTM with IAC with the help of CR and DVT and score and compare the diagnostic information obtained by CR and DVT.

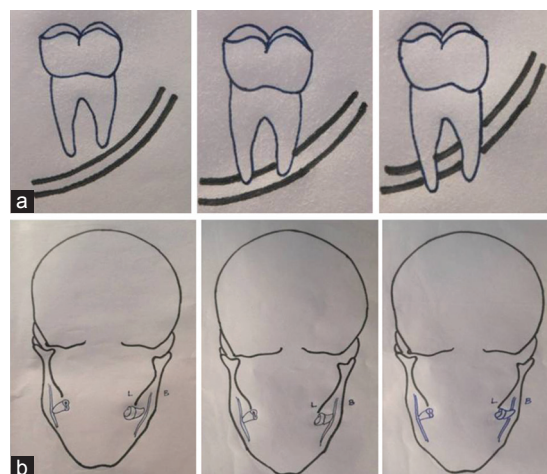
### MATERIALS AND METHODS

A total of 66 impacted MTMs in 48 patients, ages ranging from 20 to 45 years, were randomly divided into Group A (CR) and Group B (DVT) for the assessment of relationship between RTs and IAC. Patients with clinically detectable impacted MTM and radiographic evidence of impacted MTM were selected for the study. Pregnant patients and patients with pathologies such as cysts, tumors, and systemic diseases were excluded from the study. OPG was performed as an initial screening radiograph for impacted MTMs for all the patients. In Group A, apart from OPG, other conventional radiographs taken were symmetrical PA cephalometric radiograph with wide open mouth and 15° angulation (OPA), and two intraoral PRs: 0° PR and -25° PR, for impacted third molars. Only in cases where IAC was not clearly discernable in the OPA, PRs 0° and -25° were performed. The patients in Group B were subjected to DVT for the assessment of relationship of RT of impacted MTM with the IAC.

In the present study, the parameters assessed were vertically [Figure 1a], RT was assessed as superior, at level, inferior, and not detectable with respect to IAC. In the horizontal plane [Figure 1b], it was assessed as lingual, at level, buccal/vestibular, and not detectable. A similar classification for the relationship between MTM root and mandibular canal has been used by Neugebauer *et al.*<sup>[1]</sup> Wang *et al.* used the Cartesian Coordinate system where IAN was distributed on the lingual, buccal, or inferior side of the lower third molar or between the roots.<sup>[7]</sup> The image information or Diagnostic Information obtained by CR and DVT with help of 5 point scale. (1- poor, 2- fair, 3- sufficient, 4- good, 5- excellent), in both vertical and horizontal planes.

### Conventional radiography

OPG and OPA were performed by KODAK 9000C 3D Extraoral imaging system (Carestream Health, Inc., 150 Verona Street Rochester, NY 14608).



**Figure 1:** Pictorial representation for assessing (original): (a) Vertical Relationship of root-tips of impacted mandibular third molar relative to inferior alveolar canal. (b) Horizontal relationship of root-tips of impacted mandibular third molar relative to inferior alveolar canal

Planmeca Intra (OY SF-00810, Helsinki, Finland) was used to obtain PR, using intraoral Kodak Ultraspeed E film (Carestream Health, Inc. 150 Verona Street Rochester, NY 14608), and “paralleling” or “long-cone” technique, which uses film-holding instruments to position the film parallel to the long axis of the tooth under investigation. The focus–film distance was 30.48 cm. Vertical parallax method was used for the localization of the IAC.

### Digital volume tomography

KODAK 9000C 3D Extraoral imaging system was used to obtain the images, the field of view being 50 mm × 37 mm and the voxel size 76.5 μm × 76.5 μm × 76.5 μm. The impacted teeth were assessed by the 3D reconstructed volumetric image and 200 μm tomographic sections in sagittal, axial, and coronal planes. Tomographic sections were taken in curved planar reformation, a series of multiplanar reconstructions, and oblique planar reformation. Curved planar reformation is useful in displaying the arch form and providing familiar panorama-like thin-slice images such as in the study of impacted MTM in contact with IAC.<sup>[8]</sup>

### Exposure parameters

- OPG: 68–74 kilovolt (kV), 8–10 milliamperere (mA), with an exposure cycle of 13.9–15.1
- Seconds (s)
- OPA: 88–90 kV, 10 mA, and scan time of 1s
- PR: 60 kV, 8 mA, and 0.32 s
- DVT: 70–74 kV, 10 mA, with an exposure cycle of 10.8 s.

### Study performance

The assessment of images was done by four observers blinded to each other. Two maxillofacial radiologists and two oral surgeons evaluated 33 conventional images and 33 DVT images, on a computer monitor (HP L1910 19-inch liquid crystal display (LCD) monitor with 1280 × 1024 resolution), under ambient lighting conditions. One maxillofacial radiologist and one oral surgeon did the radiographic analysis

of the OPG, OPA, and PRs, while the other two evaluated the DVT images. Evaluation of the PRs took place in a diagnosis room equipped with window shades and dimmable light for standardized low ambient illumination. Interobserver evaluations were done for all the radiographs.

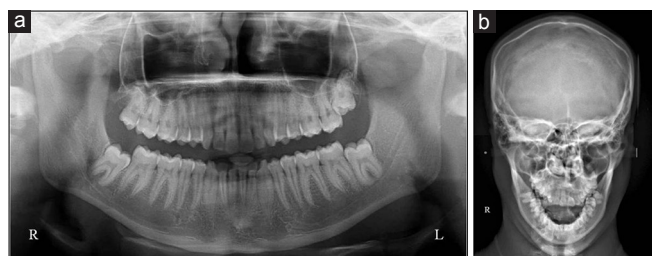Observers 1 and 3 interpreted the CR images taken for 33 impacted teeth, whereas observers 2 and 4 interpreted the DVT images taken for another 33 impacted teeth. Case illustrations have been shown in Figures 2 and 3 for CR and Figures 4 and 5 for DVT.

## Ethics

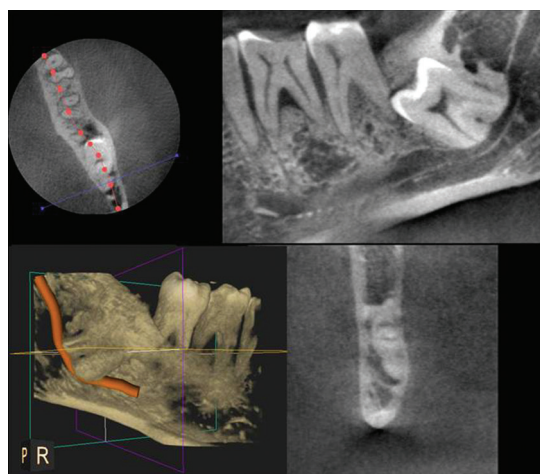
Informed consent was obtained from each patient. The ethical clearance committee of SDM College of Dental Sciences, Dharwad approved the study.

## Statistical analysis

After the data collection, the consistency of the data was checked, and descriptive and variant analysis was performed with SPSS 18.0 software (IBM Corp., USA). For the evaluation of significant differences in the ordinal data, Chi-squared tests were applied. The diagnostic information for RT and nerve position, obtained by both the imaging modalities, was calculated by subjecting it to statistical analysis with the help of Mann–Whitney U-test. Kappa statistics was done to evaluate interobserver variation.



**Figure 2:** (a) Orthopantomograph showing vertical relationship of mesial and distal root-tips of 38 and 48: at level with the inferior alveolar canal. (b) Open-mouth symmetrical postero-anterior cephalometric radiograph PA (occlusal plane angle) showing horizontal relationship of mesial and distal root-tips of 38 and 48: buccal to inferior alveolar canal



**Figure 4:** Digital volume tomography showing mesial and distal root-tips of impacted 38 at level with inferior alveolar canal in both vertical and horizontal planes

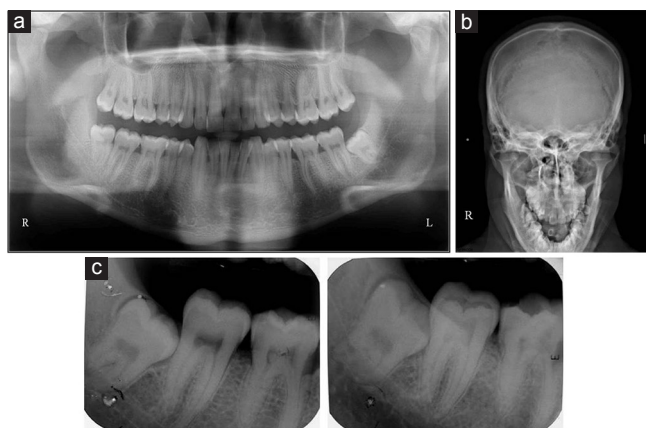
## RESULTS

The position of each RT of impacted MTM, mesial as well as distal, was separately evaluated, in both vertical and horizontal dimensions, relative to the IAC, in both Groups A and B.

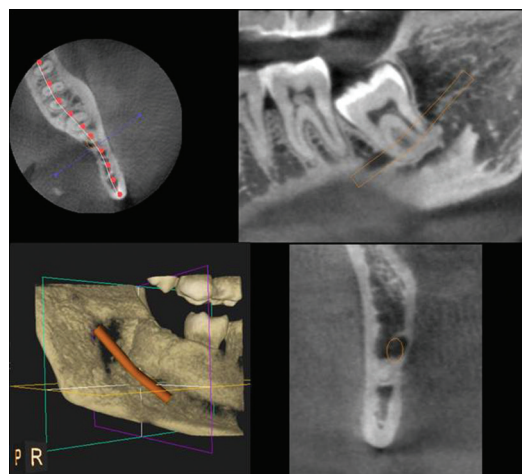
### Assessment of vertical relationship of mesial root-tip to inferior alveolar canal between Group A (MVA) and Group B (MVB)

MVA: 15.15% of the tips were superior, 63.64% at level, and 21.21% inferior to the canal.

MVB: 36.36% of the tips were superior, 36.36% at level, and 27.27% inferior to the IAC [Table 1].



**Figure 3:** (a) Orthopantomograph showing mesial and distal root-tips of 38: inferior to inferior alveolar canal (original). (b) Occlusal plane angle showing horizontal relationship of mesial and distal root-tips of 38: lingual to inferior alveolar canal (original). (c) Intraoral periapical radiographs of 38 at 0° and -25° vertical angulation: root-tips inferior and lingual to inferior alveolar canal. Canal margins appear sharper with blurred root-tip margins when root is lingual to inferior alveolar canal. Periapical radiographs, taken by modified "tube-shift" method will make a distant object move downward in relation to an object in the foreground; so, if the mandibular canal lies lingual to the impaction, it will move downwards in relation to the roots of the impacted mandibular third molar and vice-versa. In this case, the inferior alveolar canal moved upwards



**Figure 5:** Digital volume tomography showing mesial and distal root-tips of impacted 38 inferior and buccal to inferior alveolar canal



**Assessment of vertical relationship of distal root-tip to inferior alveolar canal between Group A (DVA) and Group B (DVB)**

DVA: 24.24% of the tips were superior, 48.48% at level, and 27.27% inferior to the canal.

DVB: 30.30% of the tips were superior, 45.45% at level, and 24.24% inferior to the canal [Table 2].

**Assessment of horizontal relationship of mesial root-tip to inferior alveolar canal between Group A (MHA) and Group B (MHB)**

MHA: 9.09% of the tips were “not detectable,” 36.36% were lingual, 21.21% at level, and 33.33% buccal to the IAC.

MHB: All the tips “could be assessed,” 30.30% were lingual, 39.39% at level, and 30.30% buccal to the canal [Table 3].

**Assessment of horizontal relationship of distal root-tip to inferior alveolar canal between Group A (DHA) and Group B (DHB)**

DHA: 18.18% of the tips were “not detectable,” 36.36% were lingual, 18.18% at level, and 27.27% buccal to the canal.

DHB: All the tips “could be assessed,” 24.24% of the tips were lingual, 39.39% at level, and 36.36% buccal to the canal [Table 4].

Comparison between CR and DVT for the Diagnostic Information by Mann–Whitney U-test [Table 5] showed no significant interobserver variability between the subgroups for the vertical dimension. However, the diagnostic information for the horizontal dimension was highly significant for both the mesial and distal roots, with an advantage for DVT ( $P < 0.05$  for both MH and DH).

Kappa statistics was done for interobserver agreement in both the groups. Tables 6 and 7 show interobserver agreement between observers 1 and 3 for CR (Group A) and Observers 2 and 4 for DVT (Group B), respectively. DVT showed an excellent match between interobserver readings to locate the IAC, whereas the interobserver agreement for CR with respect to MH was significant ( $P < 0.05$ , kappa value = 0.2157).

When evaluating the DVT, it was obvious that the maxillofacial surgeons used the axial section more often than the oral and maxillofacial radiologists. The latter preferred the coronal section and reformatted panoramic view with the use of the tools to mark the IAC.

**DISCUSSION**

Iatrogenic origin of neurosensory dysfunction is a distressing sequel to the surgical removal of impacted MTMs, which

**Table 1: Comparison of conventional radiography with digital volume tomography to assess the vertical relationship of mesial root-tip to inferior alveolar canal**

	CR (Group A)	Percentage	DVT (Group B)	Percentage	Total
RT not assessed	0	0.00	0	0.00	0
RT superior to the canal	5	15.15	12	36.36	17
RT at level with the canal	21	63.64	12	36.36	33
RT inferior to the canal	7	21.21	9	27.27	16
Total	33	100.00	33	100.00	66

CR: Conventional radiography, DVT: Digital volume tomography, RT: Root-tip

**Table 2: Comparison of conventional radiography with digital volume tomography to assess the vertical relationship of distal root-tip to inferior alveolar canal**

	CR (Group A)	Percentage	DVT (Group B)	Percentage	Total
RT not assessed	0	0.00	0	0.00	0
RT superior to the canal	8	24.24	10	30.30	18
RT at level with the canal	16	48.48	15	45.45	31
RT inferior to the canal	9	27.27	8	24.24	17
Total	33	100.00	33	100.00	66

CR: Conventional radiography, DVT: Digital volume tomography, RT: Root-tip

**Table 3: Comparison of conventional radiography with digital volume tomography to assess the horizontal relationship of mesial root-tip to inferior alveolar canal**

	CR (Group A)	Percentage	DVT (Group B)	Percentage	Total
RT not assessed	3	9.09	0	0.00	3
RT lingual to the canal	12	36.36	10	30.30	22
RT at level with the canal	7	21.21	13	39.39	20
RT buccal to the canal	11	33.33	10	30.30	21
Total	33	100.00	33	100.00	66

CR: Conventional radiography, DVT: Digital volume tomography, RT: Root-tip

**Table 4: Comparison of conventional radiography with digital volume tomography to assess the horizontal relationship of distal root-tip to inferior alveolar canal**

	CR (Group A)	Percentage	DVT (Group B)	Percentage	Total
RT not assessed	6	18.18	0	0.00	6
RT lingual to the canal	12	36.36	8	24.24	20
RT at level with the canal	6	18.18	13	39.39	19
RT buccal to the canal	9	27.27	12	36.36	21
Total	33	100.00	33	100.00	66

CR: Conventional radiography, DVT: Digital volume tomography, RT: Root-tip

**Table 5: Comparison of conventional radiography and digital volume tomography for the diagnostic information by Mann-Whitney U-test**

Main	Variables	CR		DVT		U	Z	P-level
		n	Rank sum	n	Rank sum			
Diagnostic information	MV	33	1162.00	33	1049.00	488.00	-0.72	0.4687
	DV	33	1144.50	33	1066.50	505.50	-0.50	0.6170
	MH	33	895.50	33	1315.50	334.50	-2.69	0.0071*
	DH	33	863.50	33	1347.50	302.50	-3.10	0.0019*

\* $P < 0.05$ . MV: Vertical relationship of mesial RT to IAC, DV: Vertical relationship of distal RT to IAC, MH: Horizontal relationship of mesial RT to IAC, DH: Horizontal relationship of distal RT to IAC. CR: Conventional radiography, DVT: Digital volume tomography, RT: Root-tip, IAC: Inferior alveolar canal, U: Mann-Whitney U test, Z: Standard deviation

**Table 6: Interobserver agreement (observers 1 and 3) for conventional radiography using Kappa statistics**

Variable	Observers	Agreement (%)	Expected agreement (%)	$\kappa$	SE	Z	Probability < Z
Relationship of RT with IAC							
MV	Observers 1 versus observers 3	90.91	68.32	0.7130	0.1257	5.6700	0.0000*
DV	Observers 1 versus observers 3	95.45	63.96	0.8739	0.1276	6.8500	0.0000*
MH	Observers 1 versus observers 3	73.74	66.51	0.2157	0.1275	1.6900	0.0453*
DH	Observers 1 versus observers 3	82.83	62.08	0.5472	0.1235	4.4300	0.0000*
Observer rating for diagnostic information (1=poor, 2=fair, 3=sufficient, 4=good, 5=excellent)							
MV	Observers 1 versus observers 3	100.00	77.47	1.0000	0.1204	8.3100	0.0000*
DV	Observers 1 versus observers 3	95.96	77.47	0.8207	0.1150	7.1300	0.0000*
MH	Observers 1 versus observers 3	96.97	67.68	0.9062	0.1197	7.5700	0.0000*
DH	Observers 1 versus observers 3	96.97	64.51	0.9146	0.1260	7.2600	0.0000*

MV: Vertical relationship of mesial RT to IAC, DV: Vertical relationship of distal RT to IAC, MH: Horizontal relationship of mesial RT to IAC, DH: Horizontal relationship of distal RT to IAC. RT: Root-tip, IAC: Inferior alveolar canal, SE: Standard error, K: Kappa value

**Table 7: Interobserver agreement (observers 2 and 4) for digital volume tomography using Kappa statistics**

Variable	Observers	Agreement (%)	Expected agreement (%)	$\kappa$	SE	Z	Probability < Z
Relationship of RT with IAC							
MV	Observers 2 versus observers 4	93.94	71.35	0.7885	0.1280	6.1600	0.0000*
DV	Observers 2 versus observers 4	91.92	74.10	0.6879	0.1240	5.5500	0.0000*
MH	Observers 2 versus observers 4	91.92	69.64	0.7339	0.1307	5.6100	0.0000*
DH	Observers 2 versus observers 4	91.92	70.80	0.7233	0.1303	5.5500	0.0000*
Observer rating for diagnostic information (1=poor, 2=fair, 3=sufficient, 4=good, 5=excellent)							
MV	Observers 2 versus observers 4	86.36	70.62	0.5359	0.1171	4.5800	0.0000*
DV	Observers 2 versus observers 4	88.64	71.42	0.6024	0.1161	5.1900	0.0000*
MH	Observers 2 versus observers 4	87.88	71.67	0.5721	0.1152	4.9700	0.0000*
DH	Observers 2 versus observers 4	88.64	71.42	0.6024	0.1161	5.1900	0.0000*

MV: Vertical relationship of mesial RT to IAC, DV: Vertical relationship of distal RT to IAC, MH: Horizontal relationship of mesial RT to IAC, DH: Horizontal relationship of distal RT to IAC. RT: Root-tip, IAC: Inferior alveolar canal, SE: Standard error, K: Kappa value

is frequently overlooked, and the risk is increased when the anatomic relation between the RT and the IAC is not exactly determined.<sup>[9]</sup> Hence, “localization” of IAC in relation to RT of impacted MTM is of utmost importance to enhance the feasibility of the surgical approach as well as determine a good prognosis postimpaction.<sup>[10]</sup> Using advanced imaging techniques, preoperative prediction of neurovascular bundle exposure is extremely useful for warning patients of the potential risk of postoperative dysesthesia and obtaining informed consent.<sup>[11]</sup> This is where DVT scores over CR.

In our study, the assessment of relationship of RT of impacted MTM with IAC in vertical dimension showed no significant difference in results between Groups A and B. However, the results were highly significant while assessing the horizontal relationship of both mesial and distal RTs to the IAC ( $P < 0.05$  for both MH and DH). In 9.09% cases, the horizontal dimension of mesial RT (MHA) in Group A was “not detectable,” whereas the horizontal relationship of distal RT (DHA) relative to IAC was “not detectable” in 18.18% of the cases. Thus, compared to DVT, CR showed a higher rate of cases where RTs were “not detectable” relative to the IAC, about 9 times for the horizontal dimension of mesial RT (MHA) and 18 times for the horizontal dimension of distal RT (DHA). Furthermore, in Group A, unassessed information was twice as much for the distal root as compared to the mesial root. These results show slight variation from those obtained by Neugebauer *et al.*,<sup>[1]</sup> where combined conventional radiologic procedures, panoramic radiograph, and symmetrical PA cephalometric radiograph showed more than 3 times higher rate of nondetectable information for horizontal position, compared with DVT. The difference in diagnostic information obtained for the horizontal dimension was highly significant, with an advantage for DVT (Spearman rho correlation  $P = 0.000$ ). For the vertical relationship of MTM to the canal, both the technologies were equally good.

The 3D reconstructed volumetric image, the coronal section, the reformatted panoramic view, and the curved planar reformation provided invaluable information for both the horizontal and vertical relationships in cases where RTs were at level or inferior to the canal. OPGs, on the other hand, were very reliable in predicting the vertical relationship of the RTs relative to the IAC.

The PRs ( $0^\circ$  and  $-25^\circ$ ) were more reliable in determining the architecture and number of roots as compared to OPG and OPA, with the highest resolution and excellent contrast of anatomic details. PRs provided good information about the location of IAC relative to RTs, whether buccal, lingual, or at level.<sup>[12]</sup>

Analysis of OPA was difficult. Correct positioning is important: the midsagittal plane of the patient and the film should coincide with each other. In our study, the patient position had been standardized; head position was made stable by means of ear rods and nose rest. Any amount of rotation leads to distortion in the image: The IAC on the side to which the patient's head

was rotated became obscured, while on the other side, the canal was better appreciated. However, a limitation of the study was that the mesial as well as the distal RTs of third molars in relation to the IAC were not clearly discernable in many cases on OPA, especially the distal RT.

DVT scores over conventional modality with a potent combination of 3D orthogonal sections, high spatial resolution, and low radiation dose. Hence, the surgeon instead of interpreting one or more additional conventional radiographs and reconstructing a 3D mental impression of the impacted MTM and its neighboring anatomic structures, can view impacted tooth in axial, coronal, and sagittal planes in one radiograph in DVT. In the present study, all the RTs were detectable in relation to the IAC using DVT. However, in two-dimensional CRs, the horizontal relationships of mesial and distal RTs relative to the IAC could not be assessed in few cases.

Standardization of evaluation was maintained. All investigators received training before the data acquisition. Apart from PRs, which were interpreted on the films, the observers interpreted all other images on the LCD monitor using visual enhancement tools and scrolling the contiguous images, thereby minimizing bias.

## CONCLUSION

In our study, DVT scored over CR in providing diagnostic information for images in the horizontal plane for both the mesial and distal roots, while in the vertical plane, there was no significant difference between CR and DVT. The effective radiation dose of standard computed tomography is significantly higher compared with DVT and four times higher than conventional radiographs, thereby raising concern for the patients who would receive significantly higher radiation exposure.<sup>[13,14]</sup> Hence, it can be safely argued that DVT should be used as the next line of examination after a screening radiograph like PR or OPG. This is a significant improvement for the maxillofacial surgeon who can give adequate information to the patient, optimize the treatment planning, maximize the benefit-to-risk ratio, and avoid unwanted complications of paresthesia, anesthesia, and dysesthesia associated with impacted MTM surgery.<sup>[15]</sup>

## Acknowledgment

The authors wish to thank Prof. C. Bhasker Rao, former Principal, and Prof. Srinath L. Thakur, Principal, SDM College of Dental Sciences and Hospital, for their sincere support to research. The authors also wish to acknowledge the assistance of the staff of the Department of Oral Medicine and Radiology in patient management and radiographic exercises. We also wish to thank Prof. Javalli, professor of statistics, for providing statistical analysis.

## Financial support and sponsorship

Nil.

Bhowmik, *et al.*: DVT versus conventional radiography in the preoperative assessment of position of inferior alveolar canal and impacted mandibular third molars

## Conflicts of interest

There are no conflicts of interest.

## REFERENCES

1. Neugebauer J, Shirani R, Mischkowski RA, Ritter L, Scheer M, Keeve E, *et al.* Comparison of cone-beam volumetric imaging and combined plain radiographs for localization of the mandibular canal before removal of impacted lower third molars. *Oral Surg Oral Med Oral Pathol Oral Radiol Endod* 2008;105:633-42.
2. Prophylactic removal of impacted third molars: Is it justified? *Br J Orthod* 1999;26:149-51.
3. Perciaccante VJ, Haug RH. Management of impacted teeth. *Oral Maxillofac Surg Clin N Am* 2007;19:1-13.
4. Archer HW. Impacted teeth. In: *Oral and Maxillofacial Surgery*. 5<sup>th</sup> ed. Philadelphia: W.B. Saunders Company; 1975. p. 250-390.
5. Richards AG. Roentgenographic localization of the mandibular canal. *J Oral Surg (Chic)* 1952;10:325-9.
6. Scarfe WC, Farman AG. What is cone-beam CT and how does it work? *Dent Clin North Am* 2008;52:707-30, v.
7. Wang WQ, Chen MY, Huang HL, Fuh LJ, Tsai MT, Hsu JT, *et al.* New quantitative classification of the anatomical relationship between impacted third molars and the inferior alveolar nerve. *BMC Med Imaging* 2015;15:59.
8. Scarfe WC, Farman AG, Sukovic P. Clinical applications of cone-beam computed tomography in dental practice. *J Can Dent Assoc* 2006;72:75-80.
9. Khan I, Halli R, Gadre P, Gadre KS. Correlation of panoramic radiographs and spiral CT scan in the preoperative assessment of intimacy of the inferior alveolar canal to impacted mandibular third molars. *J Craniofac Surg* 2011;22:566-70.
10. Nagpal A, Pai KM, Setty S, Sharma G. Localization of impacted maxillary canines using panoramic radiography. *J Oral Sci* 2009;51:37-45.
11. Vandenberghe B, Jacobs R, Bosmans H. Modern dental imaging: A review of the current technology and clinical applications in dental practice. *Eur Radiol* 2010;20:2637-55.
12. Kositbowornchai S, Densiri-aksorn W, Piumthanaroj P. Ability of two radiographic methods to identify the closeness between the mandibular third molar root and the inferior alveolar canal: A pilot study. *Dentomaxillofac Radiol* 2010;39:79-84.
13. Loubele M, Bogaerts R, Van Dijck E, Pauwels R, Vanheusden S, Suetens P, *et al.* Comparison between effective radiation dose of CBCT and MSCT scanners for dentomaxillofacial applications. *Eur J Radiol* 2009;71:461-8.
14. Ohman A, Kull L, Andersson J, Flygare L. Radiation doses in examination of lower third molars with computed tomography and conventional radiography. *Dentomaxillofac Radiol* 2008;37:445-52.
15. Lopes V, Mumenya R, Feinmann C, Harris M. Third molar surgery: An audit of the indications for surgery, post-operative complaints and patient satisfaction. *Br J Oral Maxillofac Surg* 1995;33:33-5.