

# Correlation of p53 Expression with Histopathological and Immunohistochemical Features of Human Papillomavirus in Oral Leukoplakia

Dhirendra Gururaj Sirur, Avinash Tamgadge<sup>1</sup>, Sandhya Tamgadge<sup>1</sup>, Sudhir Bhalerao<sup>1</sup>, Pavan Kumar Gujjar<sup>2</sup>

Department of Oral Pathology, SDM College of Dental Sciences and Hospital, Dharwad, Karnataka, <sup>1</sup>Department of Oral and Maxillofacial Pathology and Microbiology, D.Y Patil Deemed to be University School of Dentistry Nerul, Navi Mumbai, Sector 7, Nerul, Navi Mumbai, Maharashtra, <sup>2</sup>Department of Oral Pathology and Microbiology, Narsinhbhai Patel Dental College and Hospital, Visnagar, Gujarat, India

## Abstract

**Background:** Oral cancer is strongly associated with the habit of tobacco chewing, alcohol, and betel quid consumption in India. However, sometimes, majority of the population develop oral cancer without exposure to these risk factors and are sometimes cautious about their fitness, suggesting that additional causes such as genetic predisposition, diet, and viral agents may be associated which need to be explored. **Aims and Objectives:** The aim of this study was to establish a possible correlation between clinical types of leukoplakia with their histopathological features of high-risk human papillomavirus (HPV) infection and the presence or absence of HPV and expression of p53 through immunohistochemistry (IHC). **Materials and Methods:** Sample comprised of 40 cases of leukoplakia and 10 cases as control group. Three sections were prepared from each biopsy and subjected to IHC and hematoxylin and eosin (H and E) stain, respectively. IHC-stained slides were used to evaluate the expression of p53 and HPV and then correlated with the features of HPV infection using H and E staining. Chi-square test with a statistical analysis software package (SPSS software Version 20.0) was used. **Observation and Results:** The *P* value for p53 against HPV (IHC) was 0.012, which indicates a significant difference between positivity proportion of P53 and HPV (IHC), whereas the *P* value for koilocyte and HPV (IHC) is 0.311, which is nonsignificant and indicates no significance of difference between proportion of positivity between koilocyte and HPV (IHC). **Conclusion:** The expression of p53 was proportionally significant to the expression of positivity of HPV, but there was no significant association between koilocyte and p53 expression.

**Keywords:** Dysplasia, hematoxylin and eosin, high-risk human papillomavirus, immunohistochemistry, koilocyte, leukoplakia, p53

## INTRODUCTION

Tobacco chewing, alcohol, and betel quid consumption in India is the chief cause of oral cancer. However, nowadays, it occurs in patients who are devoid of habits and fitness cautious. Thus, there is an urgent need to explore more causative factors.<sup>[1]</sup>

Another alarming finding is that leukoplakias are showing malignant transformation more in nonsmokers than smokers, which may indicate the existence of more potent carcinogenic factors in nonsmokers.<sup>[2]</sup>

In addition, the incidence is on rise in younger patients. These drifts have led researchers to explore other potential

risk factors. Recent studies suggest that there may be an unexplored pathway for oral carcinogenesis.<sup>[3]</sup> High-risk human papillomaviruses (HPVs) have been implicated in the carcinogenesis in patients without deleterious habits.<sup>[4]</sup> HPVs are small epitheliotropic DNA viruses which reside in the skin and mucosa of several animals. More than 70 types have been described in humans. Mucosal and genital HPVs

**Address for correspondence:** Dr. Sandhya Tamgadge, Department of Oral and Maxillofacial Pathology and Microbiology, D.Y Patil Deemed to be University School of Dentistry Nerul, Navi Mumbai, Sector 7, Maharashtra, Pin - 400 706, India. E-mail: sandhya.tamgadge@gmail.com

Received: 04-07-2019 Revised: 24-01-2020  
Accepted: 23-02-2020 Published: 10-09-2020

### Access this article online

#### Quick Response Code:



**Website:**  
<http://www.jmau.org/>

**DOI:**  
10.4103/JMAU.JMAU\_44\_19

This is an open access journal, and articles are distributed under the terms of the Creative Commons Attribution-NonCommercial-ShareAlike 4.0 License, which allows others to remix, tweak, and build upon the work non-commercially, as long as appropriate credit is given and the new creations are licensed under the identical terms.

**For reprints contact:** [reprints@medknow.com](mailto:reprints@medknow.com)

**How to cite this article:** Sirur DG, Tamgadge A, Tamgadge S, Bhalerao S, Gujjar PK. Correlation of p53 expression with histopathological and immunohistochemical features of human papillomavirus in oral leukoplakia. *J Microsc Ultrastruct* 2020;8:81-8.

are divided into 30 types with low risk (HPVs 6, 11, 12, 42, 43, and 44) and high risk (HPVs 16, 18, 31, 33, 35, 45, 51, 52, and 56), according to their presence in malignant lesions of the cervix. Therefore, HPVs are now considered as human carcinogens.<sup>[5]</sup>

It is proposed that HPV-16 infection may be a risk factor for oral cancer.<sup>[3]</sup> Patients with HPV-positive oral squamous cell carcinoma (OSCC) occur at comparatively younger age group who have high-risk sexual behavior.<sup>[6]</sup>

The E6 and E7 oncoproteins encoded by HPV bind to p53 protein and to retinoblastoma (Rb) product, respectively, resulting in inactivation of them.<sup>[7]</sup> The binding of E6 protein encoded by HPV-16 and HPV-18 rapidly degrades p53 through ubiquitin-directed pathway resulting in mutations and malignant tumors of different kinds.<sup>[8,9]</sup>

HPV infection is strongly associated with cervical squamous cell carcinoma (SCC), but its association in benign and malignant oral lesions is yet to be explored completely.

However, significant correlations have been established between the presence of HPV and the degree of dysplasia. HPV is more commonly present in premalignant rather than malignant lesions. HPV-16-related virus is the predominant genotype in HPV-associated SCC, and this genotype has been demonstrated in 80% cases of oral leukoplakias.<sup>[2,10]</sup>

Therefore, this study was conducted to establish a possible correlation between histopathological features of HPV infection in leukoplakia using hematoxylin and eosin (H and E) and immunohistochemistry (IHC) with p53 marker.

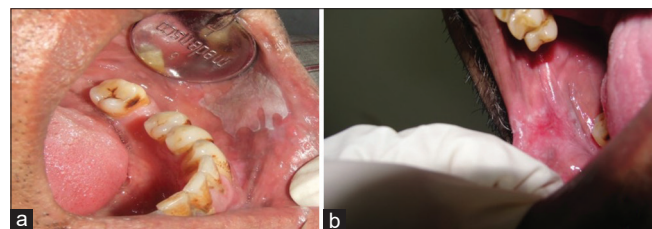
## MATERIALS AND METHODS

This case-control study was conducted at D. Y. Patil University School of Dentistry in the Department of Oral Pathology and Microbiology and Laboratory Part of Research, at Research Unit of Maratha Mandal's Nathajirao G. Halgekar Institute of Dental Sciences and Research Centre, Belgaum, from June 2011 to January 2012.

The total number of samples in the present study comprised of 50 participants: 40 cases of leukoplakia (study group) and 10 cases of normal mucosa as (control group) [Figure 1].

### Inclusion criteria

Clinically healthy persons without the history of any oral habit such as tobacco, pan, alcohol consumption, smoking of any



**Figure 1:** 1a-Homogenous Leukoplakia, 1b-Nonhomogenous leukoplakia

type, and normal-appearing oral mucosa were considered for control group.

Patients with clinically evident lesions of leukoplakia comprised study group.

### Exclusion criteria

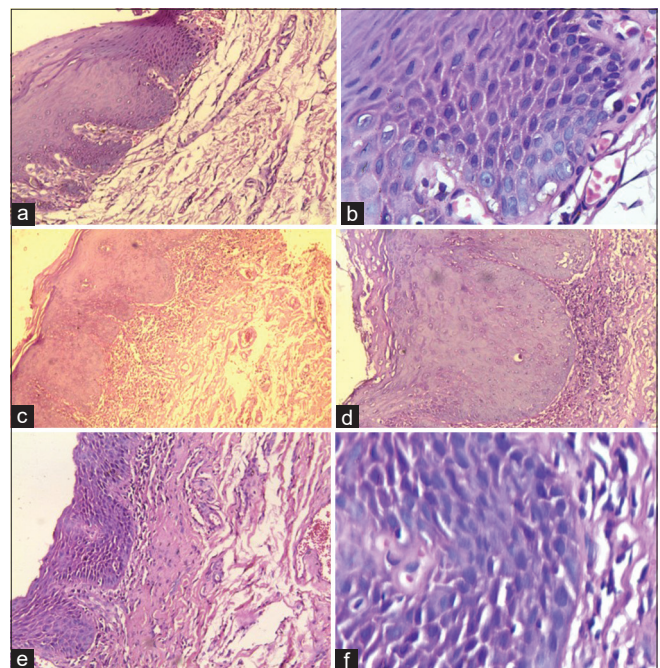
Patients on antibiotics, bleeding risk (e.g., anticoagulant therapy), chemotherapy, and/or immunosuppressant therapy, patients with endocarditis risk, patients undergoing radiation therapy in the head-and-neck region, and patients with infection risk (e.g., HIV, HBV, HCV, and tuberculosis) were excluded.

### Methodology

All the participants were administered a standard questionnaire interview to obtain the history. Ethical approval was taken from the institutional committee (PDDYPU/0878/2009) on 31 december 2009. Informed consent was obtained for participation in the study and use of the data for research and educational purposes. All the procedures follows the guidelines laid down in Declaration of Helsinki (1964). Biopsy was performed under local anesthesia under strict asepsis protocol. Leukoplakia cases were graded as homogeneous type and nonhomogeneous type (speckled) and histologically graded according to the WHO epithelial dysplastic criteria.<sup>[11]</sup> Biopsy was performed, and three sections were prepared with each biopsy and stained with H and E and the remaining two were stained with IHC (HPV and p53 markers). H and E-stained sections were also scanned to identify the features of HPV infection.

The following histological changes were considered to categorize dysplasia as mild, moderate, and severe [Figure 2]:

1. Loss of polarity



**Figure 2:** Photomicrograph of mild (a:  $\times 10$  and b:  $\times 40$ ), moderate (c:  $\times 10$  and d:  $\times 40$ ), and severe dysplasia (e:  $\times 10$  and f:  $\times 40$ )



2. Basal cell hyperplasia
3. Increased nuclear–cytoplasmic ratio
4. Bulbous rete ridges
5. Irregular epithelial stratification
6. Increased number of mitotic figures
7. Presence of mitotic figures in the superficial half of the epithelium
8. Cellular and nuclear pleomorphism
9. Nuclear hyperchromatism
10. Enlarged nucleoli
11. Loss of cohesion
12. Keratinization of single cells or cell groups in the prickle cell layer.

### Histopathological criteria of human papillomavirus infection included<sup>[12]</sup>

1. Koilocytosis – the presence of a perinuclear clear zone and pyknotic, irregularly shaped nuclei within the spinous cells of the squamous epithelium
2. Chevron keratinization characterized by the epithelial layer showing streaks of parakeratosis often extending beyond the adjacent layers giving the surface a waxy, Chevron, or “church spire” type of appearance
3. Acanthosis
4. Dyskeratosis
5. Keratinocyte multinucleation
6. Irregular keratohyalin granules
7. Mitotic epithelial cells above the basal layer [Figure 3].

### Expression of p53 and human papillomavirus

A 3- $\mu$ m section of the remaining two sections transferred to aminopropyltriethoxysilane (Sigma-Aldrich Chemical Co., USA)-coated slides and incubated at room temperature. The sections were deparaffinized in three changes of fresh xylene each for 5 min, followed by dehydration in a series of 100% absolute alcohol each for 5 min. Endogenous peroxidases were blocked with peroxide block (Biogenex Life Sciences Pvt. Ltd., CA, USA) for 15 min at room temperature and washed with distilled water, followed by citrate buffer (pH 6.0)

wash for 10 min. Antigen retrieval was undertaken with the help of Biogenex antigen retrieval system. The sections were immersed in citrate buffer solution and placed into the Biogenex antigen retrieval system and heated for 15 min. The system was allowed to cool to room temperature by placing it under running tap water, and later, the slides were washed with distilled water for 5 min. With an intention to block endogenous biotin, the sections were incubated with a blocking agent (Biogenex Life Sciences Pvt. Ltd., CA, USA) for 15 min. Excess power block solution was drained, and the one section of each patient was incubated with primary monoclonal antibody of p53 and the other with anti-HPV-16 antibody (Biogenex Life Sciences Pvt. Ltd., CA, USA) for 1 h and later thoroughly washed with citrate buffer. Sections were incubated for further enhancement of the staining, with the anti-mouse secondary antibody (super-enhancer) (Biogenex Life Sciences Pvt. Ltd., CA, USA) for 30 min, followed by two consecutive buffer washes, each for 5 min. Horseradish peroxidase (Biogenex Life Sciences Pvt. Ltd., CA, USA) was added to the sections and incubated for 30 min. The chromogen diaminobenzidine was prepared just before use by mixing one drop of chromogen to 1 ml of buffer in a mixing vial and later added over the sections. After 5 min, the sections were washed in buffer followed by water and counterstained with Harris hematoxylin, air-dried, cleared, and mounted with dibutyl phthalate xylene.

### Statistical methods

Discrete statistical data were analyzed by Chi-square test with a statistical analysis software package (SPSS software 6.0 version IBM Corp. Released 2011. IBM SPSS Statistics for Windows, Version 20.0. Armonk, NY: IBM Corp.).

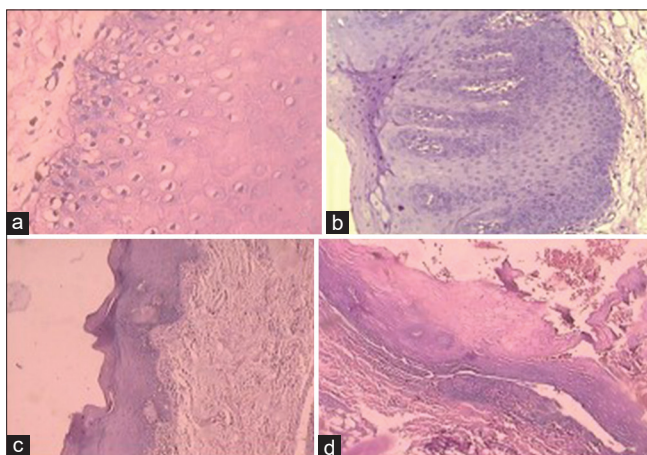
### OBSERVATION AND RESULTS

The expression of p53 (IHC) was noted in 20 out of 50 samples (both groups), and 20 of these samples were showing HPV positivity (IHC) and 32 samples were showing koilocytosis (H and E).

Z-test was applied to test the significance of proportionality. The *P* value for p53 against HPV (IHC) was 0.012, which indicates a significant difference between positivity proportion of P53 and presence of HPV, whereas the *P* value for koilocyte (H and E) and HPV (IHC) was nonsignificant (0.311) [Table 1].

The expression of p53 was positive in 16 samples study group and 4 samples of control group. Twenty of 40 samples of leukoplakia were positive for HPV infection and 32 of 40 samples are positive for koilocytosis [Tables 2 and Figures 4-6].

The *P* value for p53 (IHC) against HPV (IHC) in leukoplakia samples and koilocyte (H and E) against HPV (IHC) in leukoplakia samples was 0.010 and 0.010, respectively, which indicates a significant difference between p53 and HPV (IHC) and koilocyte (H and E) and HPV (IHC). Since



**Figure 3:** Photomicrograph of (a) koilocytes, (b) acanthosis, (c) Chevron, (d) Surface vacuolization in surface keratin layer

**Table 1: Sensitivity of koilocytes with respect to immunohistochemistry method**

Koilocytes	HPV (IHC)		Sensitivity
	Positive	Negative	
Positive	20	12	1.00 (100)
Negative	0	8	

Table shows 100% sensitivity for koilocytes with respect to IHC. HPV: High-risk human papillomavirus, IHC: Immunohistochemistry

**Table 2: Difference between positivity of the row and column parameters for total number of cases**

	HPV (IHC)	
	Z-test	P
p53	2.516	0.012
Koilocyte	1.013	0.311

The *P* value (value of significance) for p53 against HPV (IHC) is 0.012, which is less than that of 0.05 and indicates a significant difference between positivity proportion of p53 and HPV (IHC), whereas the *P* value for koilocyte and HPV (IHC) is 0.311, which is nonsignificant and indicates no significance of difference between proportion of positivity between koilocyte and HPV (IHC). HPV: High-risk human papillomavirus, IHC: Immunohistochemistry

**Table 3: Tests the significance of the difference between positivity of the row and column parameter for 40 leukoplakia cases**

p53	HPV (IHC)					
	Leukoplakia			Control		
	Positive	Negative	$\chi^2$	Positive	Negative	$\chi^2$
Positive	16	16	1.00	4	3	0.778
Negative	4	4		2	1	

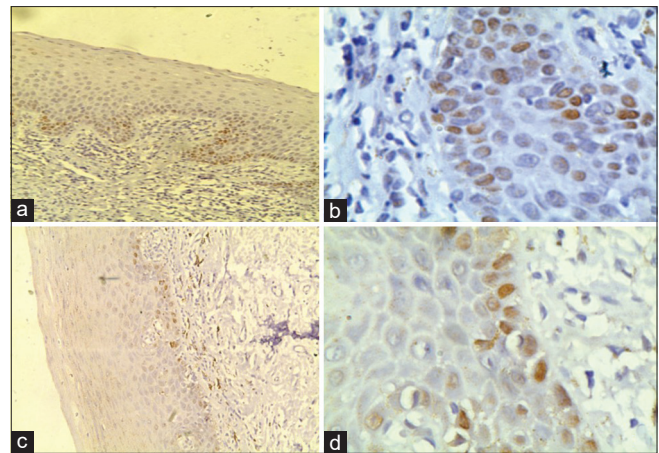
The  $\chi^2$  *P* value for HPV (IHC) (leukoplakia) against p53 is nonsignificant ( $P=1.00$ ) which is greater than that of 0.05; the positivity and negativity of HPV (IHC) (leukoplakia) and p53 are independent. Similarly, the results are nonsignificant in control group also. HPV: High-risk human papillomavirus, IHC: Immunohistochemistry

**Table 4: The values for high-risk human papillomavirus (immunohistochemistry) positivity for leukoplakia and controls independently**

	HPV (IHC) in leukoplakia samples	
	Z-test	P
p53	2.578	0.010
Koilocyte	2.578	0.010

The *P* value for p53 against HPV (IHC) in leukoplakia samples and koilocyte against HPV (IHC) in leukoplakia samples is 0.010 and 0.010, respectively, which is less than that of 0.05 and indicates a significant difference between p53 and HPV (IHC) and koilocyte and HPV (IHC). HPV: High-risk human papillomavirus, IHC: Immunohistochemistry

the above result shows the significance of difference between p53 and HPV (IHC) and koilocyte and HPV (IHC), we carried

**Figure 4:** Photomicrograph of P53 staining in (a) normal tissue  $\times 10$  and (b)  $\times 40$ , (c) hyperkeratosis  $\times 10$  and (d)  $\times 40$ 

out the analysis to check the association of leukoplakia and normal cases with HPV (IHC) positivity using Chi-square test [Tables 3 and 4].

The Chi-square *P* value for HPV (IHC) and leukoplakia was nonsignificant ( $P = 0.321$ ) [Table 5].

In the present study, 50% of the samples showed positivity for HPV infection in leukoplakia samples by IHC and 60% of the normal oral mucosal samples were positive [Table 5]. There was no significance of proportionality of the prevalence of HPV infection. Sensitivity of koilocyte was studied using IHC method, and the result showed 100% sensitivity for koilocyte [Tables 6 and 7].

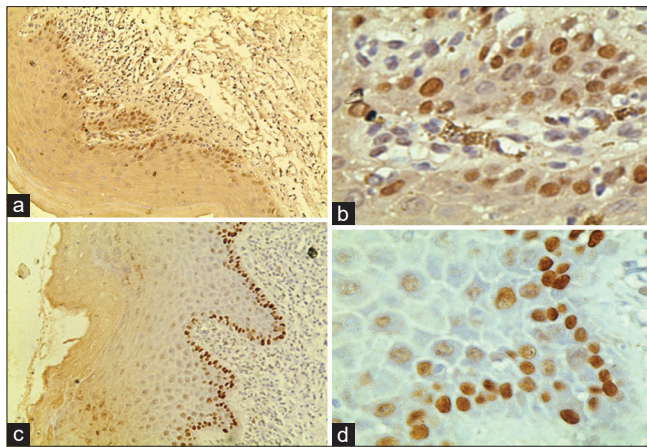
Eighty percent of the leukoplakia samples were with surface vacuolization and were also positive for HPV infection (IHC). There was a statistical significance of proportion between surface vacuolization and HPV infection in leukoplakia ( $P = 0.024$ ) [Table 8].

The appearance of Chevron-like spikes in the parakeratinized surface and positivity for HPV infection was seen in 50% of the leukoplakia samples. An equal number of cases were showing negativity for HPV infection.  $P=0.751$  does not indicate the significance of proportion [Tables 9 and 10].

Eighty-five percent of the leukoplakia cases were positive for acanthosis (histopathologically) and HPV infection, whereas 20% of the cases were negative for acanthosis but positive for HPV infection ( $P = 0.214$ ) [Table 11].

In the present study, 37.51% of the leukoplakia cases were of mild dysplasia, followed by 32.5% cases of hyperkeratotic lesion without dysplasia, and moderate and severe cases of dysplasia were 25% and 5%, respectively, in 40 cases of leukoplakia [Table 12].





**Figure 5:** Photomicrograph of P53 staining in mild (a:  $\times 10$  and b:  $\times 40$ ) and moderate (c:  $\times 10$  and d:  $\times 40$ )

**Table 5: The values for leukoplakic lesions with high-risk human papillomavirus infection**

HPV (IHC)	Leukoplakia	Control	$\chi^2$ (P)
Positive	20	6	0.321
Negative	20	4	

The  $\chi^2$  P value for HPV (IHC) and leukoplakia is nonsignificant ( $P=0.321$ ) which is greater than that of 0.05. Since the value for HPV (IHC) is (0.321) nonsignificant, the attributes of high-risk human papillomavirus (IHC) and leukoplakia are independent. HPV: High-risk human papillomavirus, IHC: Immunohistochemistry

**Table 6: Sensitivity of koilocytes with respect to immunohistochemistry method**

Koilocytes	HPV (IHC)		Sensitivity (%)
	Positive	Negative	
Positive	20	12	1.00 (100)
Negative	0	8	

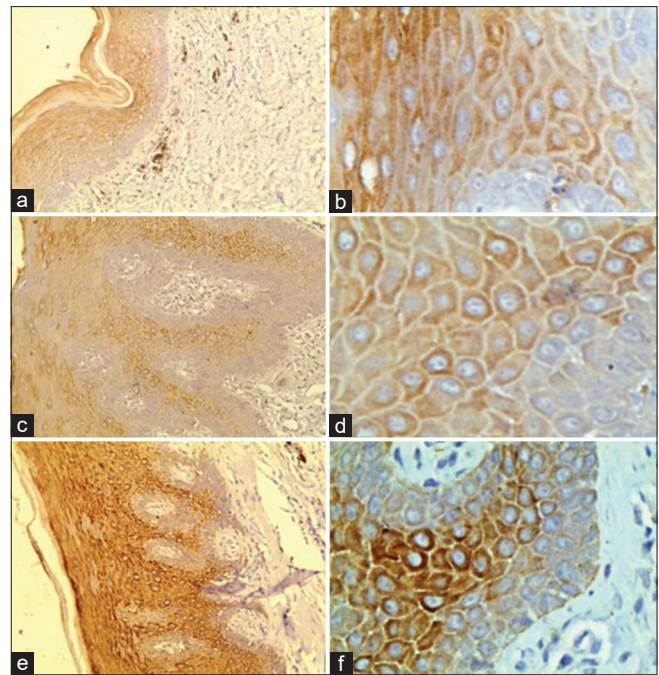
This table shows 100% sensitivity for koilocytes with respect to IHC. HPV: High-risk human papillomavirus, IHC: Immunohistochemistry

**Table 7: Profile distribution of study samples and their association with high-risk human papillomavirus infection**

Lesion	Total number of cases	HPV IHC Positive	Percentage of IHC (HPV)-positive cases
Leukoplakia	40	20	50
Normal	10	6	60
P		0.832	

HPV: High-risk human papillomavirus, IHC: Immunohistochemistry

The result shows 76.92% of HPV positivity with hyperkeratotic lesion, followed by 46.66% of the cases with mild dysplasia, and 30% of the cases were of moderate dysplasia. There was no HPV infection positivity in two cases of severe dysplasia [Table 12].



**Figure 6:** Photomicrograph of human papillomavirus staining in mild (a:  $\times 10$  and b:  $\times 40$ ), moderate (c:  $\times 10$  and d:  $\times 40$ ), and severe (e:  $\times 10$  and f:  $\times 40$ )

## DISCUSSION

HPV is a member of the Papillomaviridae family that infects epithelial cells exclusively. The association of HPV types 16 and 18 with neoplasms of the uterine cervix is well recognized.<sup>[13]</sup> After infecting epithelial basal layer, virus replicates in the nuclei of the infected cells, which produces mature virions in the suprabasal layers. Oral HPV infection can be acquired by oral-genital contact, by mouth-to-mouth contact, or possibly by autoinoculation and in infants by mother-to-child transmission.<sup>[14]</sup>

p53 and Rb are significant tumor suppressor genes, which maintain cell cycle regulation, protect cellular repair processes, and are involved in programmed cell death or apoptosis.<sup>[15]</sup>

The aggressive behavior of HPV is considered to be due to two oncoproteins, E6 and E7. The E6 protein has been shown to interact with the p53 protein and promote its degradation by means of an ubiquitin pathway. The E7 oncoprotein can similarly complex with the Rb protein and inactivate it. Hence, this research to assess the expression of p53 in the presence of HPV in oral leukoplakia using IHC and H and E staining.

The present study showed that HPV positivity was mainly in the stratum spinosum and no staining was evident in the parakeratinized layer. Positivity was observed in classic koilocytes and also with nonclassic histologic HPV cells, which is similar to that reported by Varnai *et al.*,<sup>[16]</sup> but they reported

HPV positivity in the parakeratinized layer and occasionally in cells with apparently normal morphology as well. They had utilized chromogenic *in situ* hybridization technique.

In contrast to the present study, Bouda *et al.*<sup>[11]</sup> analyzed hyperplastic dysplastic and SCC cases. The nested polymerase chain reaction (PCR) analyses detected 48 of 53 (90.6%) positive cases of HPV, and none of the normal samples were infected. HPV was detected in 5 of 5 dysplasias (100%) and 18 of OSCC. There was no association between HPV infection, histology, and classic HPV changes, but Yaltirik *et al.*<sup>[17]</sup> detected one case of leukoplakia with moderate koilocytosis and two cases of mild koilocytosis in the surface epithelium. Additionally parakeratosis was observed in one case and hyperkeratosis in three cases, whereas in the present study, parakeratosis was observed in 25 (56%) cases and 15 (40%) cases of orthokeratosis with 20 (50%) cases of HPV positivity. Whereas, V. E. Furrer *et al.*<sup>[18]</sup> reported 48% cases of positive koilocytosis in their study. The present study shows a clear statistical significance of koilocytosis in the lesion.

The present study shows acanthosis and HPV positivity in 17 of 40 (42.5%) cases, and 11 of 40 (27.5%) of the cases did not show acanthosis nor HPV positivity.

**Table 8: Profile distribution of leukoplakia cases according to surface vacuolization and their association with high-risk human papillomavirus infection**

Surface vacuolization	IHC (HPV)		
	Positive	Percentage of HPV positivity	Negative
Positive	16	80	8
Negative	4	20	12
<i>P</i> ( $\chi^2$ )		0.024	

HPV: High-risk human papillomavirus, IHC: Immunohistochemistry

**Table 9: Profile distribution of leukoplakia cases according to Chevron keratinization histopathologically and their association with high-risk human papillomavirus infection**

Chevron keratinization	IHC (HPV)		
	Positive	Positivity (%)	Negative
Positive	10	50	12
Negative	10	50	8
<i>P</i> ( $\chi^2$ )		0.751	

HPV: High-risk human papillomavirus, IHC: Immunohistochemistry

**Table 10: Profile distribution of surface keratinization in leukoplakia and their association with high-risk human papillomavirus infection**

Keratinization	Total number of cases Leukoplakia	Percentage of leukoplakia cases	HPV IHC Positive	Percentage of HPV positivity
Parakeratinization	25	62.5	14	56
Orthokeratinization	15	37.5	6	40
<i>P</i>		0.514		

HPV: High-risk human papillomavirus, IHC: Immunohistochemistry

In a study published by Koyama *et al.* to detect HPV infection using *in situ* methods to examine HPV infection (HPV-16, HPV-18, HPV-22, HPV-38, and HPV-70), positive cells were observed not only in koilocytes but also in morphologically normal cells. HPV-16-positive cells were scattered in the parakeratinized layer of the nonneoplastic epithelium. The present study showed HPV positivity in the koilocytes in the spinous layer but not in the parakeratinized layer which is almost in congruent with the published report,<sup>[19]</sup> and this difference in expression is probably due to the different methodologies utilized.

In the current study, an increased prevalence of HPV was observed in hyperkeratosis, followed by mild and moderate dysplasia, but there were no signs of HPV in two cases of severe dysplasia which is not in tandem with a study published by Acay<sup>[20]</sup> using *in situ*. Data published by Bouda *et al.*<sup>[11]</sup> showed 25 of 29 hybridization. (86.2%), 5 of 5 dysplasias (100%), and 18 of OSCC positivity of HPV, which is not congruent with the present study.

Cianfriglia *et al.*<sup>[21]</sup> published the data similar to our study with 57% dysplastic lesions and 61% hyperplastic lesions were positive for HPV. There was no statistical significance in relation to epithelial dysplasia.

The present study does not confirm with an earlier study published by Mousami Majumdar.<sup>[22]</sup> Most of the leukoplakia patients suffered from moderate (57% and 54%), followed by mild (27% and 26%) and severe (16% and 12%) dysplasia in HPV infected and noninfected samples, respectively, but only a few had hyperplasia (10% and 8%).

Our study shows 50% (20/40) positive cases of HPV and 60% (6/10) of normal oral mucosa which is not congruent to the findings of Bouda *et al.*<sup>[11]</sup> where the nested PCR analyses detected 48 of 53 (90.6%) positive cases of HPV and none of the normal samples were infected, and Acay<sup>[20]</sup> found an overall prevalence of HPV infection was 24%, markedly higher than that found in the control group, which reports a higher prevalence of HPV in leukoplakia than in normal oral mucosa.

HPV detection in the present study is not significantly related to the presence of leukoplakia in nonhomogeneous (4/11, 55.17%) or homogeneous variants (16/29, 36.36%), which is congruent with a study published by Campisi *et al.*<sup>[23]</sup> Only histologically confirmed cases with 90 healthy samples with

no evidence of oral mucosal lesions were included in the study, and HPV detection was not significantly related to the presence of leukoplakia in nonhomogeneous (3; 13.0%) or homogeneous variants (9, 20.0%). Similar findings were reported by Cianfriglia *et al.*<sup>[21]</sup> These findings suggest that the nonhomogeneous appearance of the lesion may be a guide for the detection of HPV infection.

Sixty-seven percent of potentially malignant and malignant lesions were HPV positive by clinical criteria, which was reported by Furrer *et al.*<sup>[18]</sup> in a study of 33 individuals (21 men and 12 women) with a mean age of 58.7 years and the control group consisted of 23 individuals (6 men and 17 women) with a mean age of 38.1 years with clinically normal mucosa, utilizing PCR-Southern blot analysis, whereas our study showed HPV positivity in 85.71% of papillary appearance of the lesion and 42.42% of flat-surfaced lesions. The detection of HPV is not significantly related to the clinical surface appearance of the lesion, but the papillary surface may be suggestive of HPV infection.

In the present study, the expression of p53 in leukoplakia was detected and occurred mainly in the basal layer of epithelium, similar to that observed in the earlier studies Fan *et al.*<sup>[24]</sup> The expression of p53 in leukoplakia was detected and occurred mainly in the basal layer in the present study. Furthermore, the study of Lawall Mde and Marcelo Crivelini,<sup>[25]</sup> who immunohistochemically studied leukoplakia cases and assessed expression of p53 and PCNA in nondysplastic leukoplakias, to correlate the results with the degree of epithelial keratinization, found that most of leukoplakias showed p53 and PCNA expression in their different keratinization degrees. The p53 marking was confined to the basal and parabasal layers. The present study shows a statistically significant expression of p53.

**Table 11: Profile distribution of leukoplakia cases according to acanthosis histopathologically and their association with high-risk human papillomavirus infection**

Acanthosis	IHC (HPV)		
	Positive	Percentage of positivity	Negative
Positive	17	85	11
Negative	4	20	8
$\chi^2$ (P)		0.214	

HPV: High-risk human papillomavirus, IHC: Immunohistochemistry

**Table 12: Profile distribution of leukoplakia cases according to the grade of dysplasia and their relation to high-risk human papillomavirus infection**

Histological type	Total number of cases Leukoplakia	Percentage of leukoplakia cases	HPV IHC Positive	Percentage of HPV positivity
Hyperkeratosis	13	32.5	10	76.92
Mild dysplasia	15	37.5	7	46.66
Moderate dysplasia	10	25	3	30
Severe dysplasia	2	5	0	0

HPV: High-risk human papillomavirus, IHC: Immunohistochemistry

In our study, HPV-16 was detected in 16 of 32 p53-positive cases of leukoplakia. There was no statistical association of p53 with HPV infection in our study, which is in congruent with a study reported by Gopalakrishnan *et al.*<sup>[23]</sup> They suggest that HPV infection along with p53 expression role needs to be defined further due to limited no. of cases. p53 IHC, p53 gene mutation, and HPV prevalence do not provide means to differentiate between leukoplakia and carcinoma and do not provide a predictive test for progression of leukoplakia to carcinoma.

Haraf *et al.*<sup>[8]</sup> in patients with SCC of the head and neck found that 24% of the patients had p53 mutations and 18% were positive for HPV infections, whereas in our study of leukoplakia, we found that 80% of the patients expressed p53 and 50% were positive for HPV with a significant statistical significance, suggesting that HPV may be involved in the development of these cancers in patients.

Campisi *et al.*<sup>[26]</sup> suggest that HR-HPV is able to transform epithelia through expression of the viral oncoproteins E6 and E7 causing deregulation of cell cycle and apoptotic pathways.

In our study, we observed 9 of 13 (69.29%) cases of hyperkeratosis lesion, positive for p53 and HPV infection, and 2 of 13 (15.38%) cases are negative for HPV infection but positive for p53, suggesting that there is no statistical association between expression of p53 and HPV infection.

The present study utilizing the IHC method shows that p53 expression is of significance, but the presence of HPV does not show any significant association with p53 expression.

## CONCLUSION

Assuming IHC to be a standard method, we conduct sensitivity of koilocytes with respect to IHC method, and the result shows 100% sensitivity for Koilocytes with respect to IHC.

The expression of p53 is proportionally significant to the expression of positivity of HPV, but there is no significant association between HPV and p53 expression, hence suggesting that p53 is certainly a good prognosticator of the status of leukoplakia, but the presence of HPV has no significant bearing on the expression of p53.



The presence of HPV in normal oral mucosa in the absence of any significant habit suggests that there might be a synergistic action of HPV and habits in malignant transformation of the leukoplakia lesion.

### Financial support and sponsorship

Nil.

### Conflicts of interest

There are no conflicts of interest.

## REFERENCES

- Bouda M, Gorgoulis VG, Kastrinakis NG, Giannoudis A, Tsoi E, Danassi-Afentaki D, *et al.* "High risk" HPV types are frequently detected in potentially malignant and malignant oral lesions, but not in normal oral mucosa. *Mod Pathol* 2000;13:644-53.
- Silverman S Jr., Gorsky M, Lozada F. Oral leukoplakia and malignant transformation. A follow-up study of 257 patients. *Cancer* 1984;53:563-8.
- Mork J, Lie AK, Glatte E, Hallmans G, Jellum E, Koskela P, *et al.* Human papillomavirus infection as a risk factor for squamous-cell carcinoma of the head and neck. *N Engl J Med* 2001;344:1125-31.
- Tandle AT, Sanghvi V, Saranath D. Determination of p53 genotypes in oral cancer patients from India. *Br J Cancer* 2001;84:739-42.
- Nair S, Pillai MR. Human papillomavirus and disease mechanisms: Relevance to oral and cervical cancers. *Oral Dis* 2005;11:350-9.
- Schwartz SM, Daling JR, Doody DR, Wipf GC, Carter JJ, Madeleine MM, *et al.* Oral cancer risk in relation to sexual history and evidence of human papillomavirus infection. *J Natl Cancer Inst* 1998;90:1626-36.
- Werness BA, Levine AJ, Howley PM. Association of human papillomavirus types 16 and 18 E6 proteins with p53. *Science* 1990;248:76-9.
- Haraf DJ, Nodzenski E, Brachman D, Mick R, Montag A, Graves D, *et al.* Human papilloma virus and p53 in head and neck cancer: Clinical correlates and survival. *Clin Cancer Res* 1996;2:755-62.
- Reithdorf S, Friedrich RE, Ostwald C, Barten M, Gogacz P, Gundlach KK, *et al.* p3 mutations and HPV infection in primary head and neck squamous cell carcinomas do not correlate with overall survival: along-term follow-up study. *J Oral Pathol Med* 26: 315-321, 1997.
- Lawton G, Thomas S, Schonrock J, Monsour F, Frazer I. Human papillomaviruses in normal oral mucosa: A comparison of methods for sample collection. *J Oral Pathol Med* 1992;21:265-9.
- Okazaki Y, Tanaka Y, Tonogi M, Yamane G. Investigation of environment factors for diagnosing malignant potential in oral epithelial dysplasia. *Oral Oncol* 2002;38:562-73.
- Greer RO Jr., Schroeder KL, Crosby L. Morphologic and immunohistochemical evidence of human papillomavirus capsid antigen in smokeless tobacco keratoses from juveniles and adults. *J Oral Maxillofac Surg* 1988;46:919-29.
- Al-Bakkal G, Ficarra G, McNeill K, Eversole LR, Sterrantino G, Birek C. Human papilloma virus type 16 E6 gene expression in oral exophytic epithelial lesions as detected by in situ rtPCR. *Oral Surg Oral Med Oral Pathol Oral Radiol Endod.* 1999 Feb. 87(2):197-208. [Medline].
- Feller L, Khammissa RA, Wood NH, Lemmer J. Epithelial maturation and molecular biology of oral HPV. *Infect Agent Cancer* 2009;4:16.
- Sisk EA, Soltys SG, Zhu S, Fisher SG, Carey TE, Bradford CR. Human papillomavirus and p53 mutational status as prognostic factors in head and neck carcinoma. *Head Neck* 2002;24:841-9.
- Varnai AD, Bollmann M, Bankfalvi A, Kovacs K, Heller H, Schmitt C, *et al.* The prevalence and distribution of human papillomavirus genotypes in oral epithelial hyperplasia: Proposal of a concept. *J Oral Pathol Med* 2009;38:181-7.
- Yaltirik M, Ozveren A, Alatli C, Buyukakyuz N. Detection of human papilloma virus in benign malignant and pre-cancerous lesions of oral mucosa by *in situ* hybridization. *Turk J Med Sci* 2001;31:509-15.
- Furrer VE, Benitez MB, Furnes M, Lanfranchi HE, Modesti NM. Biopsy vs. superficial scraping: Detection of human papillomavirus 6, 11, 16, and 18 in potentially malignant and malignant oral lesions. *J Oral Pathol Med* 2006;35:338-44.
- Koyama K, Uobe K, Tanaka A. Highly sensitive detection of HPV-DNA in paraffin sections of human oral carcinomas. *J Oral Pathol Med* 2007;36:18-24.
- Acay R, Rezende N, Fontes A, Aburad A, Nunes F, Sousa S. Human papillomavirus as a risk factor in oral carcinogenesis: A study using *in situ* hybridization with signal amplification. *Oral Microbiol Immunol* 2008;23:271-4.
- Cianfriglia F, Di Gregorio DA, Cianfriglia C, Marandino F, Perrone Donnorso R, Vocaturo A. Incidence of human papillomavirus infection in oral leukoplakia. Indications for a viral aetiology. *J Exp Clin Cancer Res* 2006;25:21-8.
- Majumder M, Indra D, Roy PD, Datta S, Ray JG, Panda CK, *et al.* Variant haplotypes at XRCC1 and risk of oral leukoplakia in HPV non-infected samples. *J Oral Pathol Med* 2009;38:174-80.
- Gopalakrishnan R, Weghorst CM, Lehman TA, Calvert RJ, Bijur G, Sabourin CL, *et al.* Mutated and wild-type p53 expression and HPV integration in proliferative verrucous leukoplakia and oral squamous cell carcinoma. *Oral Surg Oral Med Oral Pathol Oral Radiol Endod* 1997;83:471-7.
- Fan GK, Chen J, Ping F, Geng Y. Immunohistochemical analysis of P57(kip2), p53 and hsp60 expressions in premalignant and malignant oral tissues. *Oral Oncol* 2006;42:147-53.
- Lawall Mde A, Crivelini MM. PCNA and p53 expression in oral leukoplakia with different degrees of keratinization. *J Appl Oral Sci* 2006;14:276-80.
- Campisi G, Panzarella V, Giuliani M, Lajolo C, Di Fede O, Falaschini S, *et al.* Human papillomavirus: Its identity and controversial role in oral oncogenesis, premalignant and malignant lesions (review). *Int J Oncol* 2007;30:813-23.