



## Quantitative assessment of the relationship of mandibular canal with impacted third molars: A retrospective analysis of cone beam computed tomographic evaluation in Dharwad population, India

*Kruthika Satyabodh Guttal MDS<sup>1</sup>, Shantala Arun Kumar MDS<sup>2</sup>,  
Krishna Burde MDS<sup>1</sup>*

### Original Article

#### Abstract

**BACKGROUND AND AIM:** Impacted third molars tend to pose certain problems varying from pain, repeated pericoronitis, bone loss with adjacent teeth, etc. The surgical removal of impacted teeth requires appropriate planning to avoid complications. Cone beam computed tomography (CBCT) is an important radiographic tool that facilitates appropriate treatment planning. This retrospective analysis of the existing orthopantomographs (OPG) and CBCT images of third molars was conducted to assess the topographic relationship between impacted mandibular third molar and the inferior alveolar nerve (IAN) canal.

**METHODS:** In this study, 124 OPGs and CBCT images were used to assess the type of impactions and evaluate the relationship of impacted teeth with the IAN.

**RESULTS:** Mesioangular impaction was the most commonly observed type of impaction followed by vertical, horizontal, and distoangular impactions. The most commonly observed relationship was mandibular canal running apically or buccally with respect to the impacted tooth but without being in contact with it.

**CONCLUSION:** The classification utilizing the topographic relationship of the impacted mandibular third molar with the IAN canal gives a clear position of the IAN to the impacted teeth. The use of digital volume tomography (DVT) for radiographic assessment reveals the relationship in axial, coronal, and sagittal dimensions, which facilitates appropriate treatment planning to avoid post-operative complications.

**KEYWORDS:** Third Molars; Cone Beam Computed Tomography; Mandibular Nerve

**Citation:** Guttal KS, Kumar SA, Burde K. Quantitative assessment of the relationship of mandibular canal with impacted third molars: A retrospective analysis of cone beam computed tomographic evaluation in Dharwad population, India. J Oral Health Oral Epidemiol 2021; 10 (4): 225-30.

Impaction of teeth is a pathological condition where a tooth fails to reach its normal functional position in the oral cavity. Third molars are among the more commonly impacted teeth accounting for nearly two thirds of all impacted teeth.<sup>1</sup> Third molars are the last teeth to erupt, which may remain asymptomatic, or cause symptoms such as pain, repeated inflammation or infections of pericoronal flaps, and can also be associated with pathologies ranging from external resorption

of adjacent roots to cysts and tumors. Therefore, the surgical removal of impacted third molars is highly advocated.<sup>1</sup> Radiographic investigation has been developed as an integral part of diagnosis of the condition and in planning the appropriate treatment of impacted third molars. It allows the oral and maxillofacial surgeon to assess the position of the impacted tooth and its relationship with the surrounding structures. Over the years, cone beam computed tomography (CBCT) has emerged as an

1- Professor, Department of Oral Medicine and Radiology, SDM College of Dental Sciences and Hospital, Shri Dharmasthala Manjunatheshwara University, Sattur, Dharwad, India

2- Assistant Professor, Department of Oral Medicine and Radiology, SDM College of Dental Sciences and Hospital, Shri Dharmasthala Manjunatheshwara University, Sattur, Dharwad, India

Address for correspondence: Kruthika Satyabodh Guttal MDS; Professor, Department of Oral Medicine and Radiology, SDM College of Dental Sciences and Hospital, Shri Dharmasthala Manjunatheshwara University, Sattur, Dharwad, India; Email: drkruthika@sdmuniversity.edu.in

accurate means of radiographic assessment.<sup>1</sup> Several classifications have been proposed in the literature for assessing the position of the impacted third molars,<sup>2</sup> and the earlier classifications such as Winter's classification, and the Pell and Gregory classification have been widely adopted for clinical practice. But they have certain limitations such as little value for predicting the degree of extraction difficulty and so on.<sup>2</sup>

Various imaging modalities have been employed for classifying impacted third molars; each modality has its own advantages and disadvantages. Till date, panoramic radiographs [orthopantomographs (OPGs)] seem to be one of the most commonly advised radiographs to establish the impaction status. The main disadvantages of OPGs include two-dimensional (2D) images, overlapping of structures, and possible image distortion. Since its inception, CBCT has grown to be the most sought-after alternative imaging technique because of its inherent advantages like cross-sectional images with good spatial resolution, clarity in nerve root relationship, option of three-dimensional (3D) images, and submillimeter spatial resolution, which profoundly influence appropriate treatment planning.<sup>3</sup> Various researchers have emphasized the importance of assessment of the positional relationship of the mandibular canal with corresponding third molars which will aid as a key anatomic factor for assessment of the inferior alveolar nerve (IAN) injury.<sup>4</sup> In addition to the relationship of mandibular third molars, the angulation and position of the impacted molars also serve as predictors for the IAN injury.<sup>5</sup> For routine evaluation, it was observed that pathologies associated with the third molar were more often observed in CBCT than in OPGs.<sup>6</sup> CBCT has paved its way to be an inevitable part of preoperative assessment, and employing CBCT is justified as it will aid in providing radiographic signs which could relate the associated high risk of IAN injury and post-operative neurosensory disturbance.<sup>7-9</sup> This significantly affects the surgical treatment planning and preparedness

for the complications.

Maglione et al. proposed a new classification for impacted mandibular third molars based on the findings from cross-sectional images of CBCT.<sup>10</sup> The classification aimed to improvise and determine the topographic relation of the impacted mandibular third molar with the IAN to improvise the estimation of the risk of injury to the IAN. The present study aimed to objectively quantify the topographic relationship of the impacted third molars with IAN in the regional population by retrospective assessment of CBCT images using the above-mentioned classification.

## Methods

In this retrospective cross-sectional study, the images from database of Oral Radiology Section of SDM College of Dental Sciences and Hospital, Shri Dharmasthala Manjunatheshwara University, Sattur, Dharwad, India, were reviewed. Prior to the retrospective analysis of the images, ethical clearance was obtained from the Institutional Review Board (Ethical code: IRB No. 2018/S/OM/45). A single calibrated reviewer examined the CBCT images and OPGs taken using Kodak 9000C machine were referred for pre-operative evaluation of third molar removal. The images were selected by convenience sampling method, i.e., OPGs/CBCTs which showed impacted third molars were selected.

The sample size to analyze the different nerve root relationship was computed using G\*Power software, based on the values obtained from the previous study by Maglione et al.<sup>10</sup> The analysis was performed with values set at  $\alpha$  error probability = 0.05 and Power ( $1-\beta$  error probability) = 0.8. The sample size was estimated to be 124.

The inclusion criteria included OPG and digital volume tomography (DVT) with impacted mandibular third molars either unilateral or bilateral.

The exclusion criteria included impacted third molars with associated pathologies, the presence of periodontal disease with adjacent

teeth, and decay with impacted teeth.

The images were acquired using a CBCT scanner (Kodak 9000C). The technical parameters used were: 90 kV, 8 mA, 10.8, scan time < 12 s, and field of view (FOV) of 4 × 6 cm. The maximum dose of exposure was 231 mg/cm<sup>2</sup>. The slice thickness of axial images was 0.25 mm. The images were analyzed in Digital Imaging and Communications in Medicine (DICOM) format and evaluated by axial, coronal, and sagittal dimensions, with a thickness of 1 mm. The DICOM software was analyzed using the CS imaging software (version CS imaging patient browser 7.0.18.5.d11, CS data manager 4.2.9.0).

Assessments undertaken were as follows:

1. Assessment of the third molar's position, angulation, depth on OPG according to the Winter's classification
2. Assessment of the relationship of impacted third molar with IAN on CBCT images according to the Maglione et al. classification<sup>10</sup>

For the CBCT sections, all the slices were thoroughly examined followed by delineation and tracing of the nerve canal option (in built-in software). This was followed by the

identification of appropriate section in coronal view depicting the canal's cross-section in maximum dimension. This section was utilized to assess the relationship between the nerve and root, according to the classification mentioned (Figure 1).

The data were analyzed using SPSS software (version 18, SPSS Inc., Chicago, IL, USA). Percentage was calculated for gender distribution and different types and levels of impactions. To calculate the gender distribution of different nerve root relationship and distribution of different classes of nerve root relationships, chi-square test was used. Statistical significant level was considered at  $P \leq 0.001$ .

## Results

The age range of subjects was 18-72 years. 124 DVT scans were analyzed, of which 44 belonged to men and 80 belonged to women. The highest impaction was mesioangular, followed by vertical, horizontal, and distoangular. The highest depth distribution belonged to type A, followed by types B and C (Table 1).

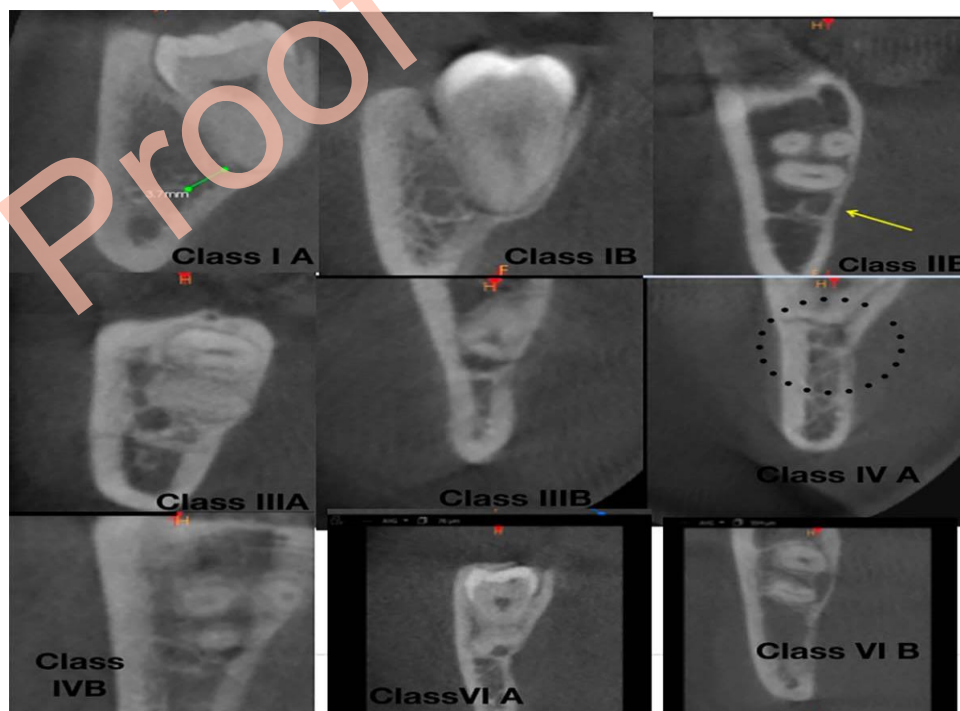


Figure 1. Different classes of nerve root relationships

**Table 1.** Frequency of type and levels of impactions

Types of impaction	Frequency	Levels	Frequency
Horizontal	32	A	38
Vertical	38	B	17
Distal	10	C	69
Mesioangular	44		

According to the nerve root compression classification, the observed patterns were class 1, 2, 3, and 6 (Figure 1).

Class 1 was the most commonly observed type (Table 2).

**Table 2.** Distribution of various classes of nerve root relationship of impacted third molars among men and women

Class	Subtype	Women	Men
1	A	9	45
	B	36	16
2	B	6	6
3	A	5	19
	B	14	2
4	A	1	8
	B	7	0
6	A	1	2
	B	1	2
Total		80	

Chi-square value1: 1.058, P = 0.198

In addition, class 1 was higher in women compared to men. After categorizing the relationships as non-contact and contact of the IAN with impacted third molars, it was revealed that the number of non-contact relationships was higher than the contact ones. Moreover, the buccal course in non-contact relationship was the dominant observed pattern.

## Discussion

Surgical removal of impacted third molars is one of the commonly undertaken procedures. Meticulous pre-operative evaluation is mandated to avoid post-operative complications like paresthesia. The various clinical and anatomic parameters including age, gender, types of anesthesia used, surgical techniques employed, and most importantly, anatomical relationship between the inferior alveolar canal and the third molar roots were

known to be associated with IAN damage.<sup>11</sup>

With the advances in diagnostic radiology, pre-operative assessment of impacted tooth is an easier task, facilitating appropriate planning. The assessment of nerve root relationship radiographically benefits appropriate treatment planning to avoid complications. In the present study, the classification proposed by Maglione et al.<sup>10</sup> was used; accordingly, class 1 type, i.e., the buccal course of the nerve, was the most commonly observed pattern. In the present study, based on the depth, level A was the most commonly observed level and level C was the least observed one, which is consistent with the results of other studies.<sup>1</sup> Similar results were observed by various other studies.<sup>4,5,12,13</sup>

Comparison of the results with those of previous studies done in Indian population showed that the results were similar and consistent with the results of few other studies.<sup>13,14</sup> The present study showed the highest prevalence of mesioangular impactions, which is consistent with the results of previous studies.<sup>15</sup> Besides, this study is the first study which used the mentioned classification for assessment of the relationship of impacted third molars with nerve root in multiple dimensions. Few studies have shown that the risk of damage to the IAN increases if third molars intersect with the mandibular canal, particularly, on its buccal side;<sup>16-18</sup> this emphasizes the importance of such detailed assessments of nerve root relationship.

The IAN injury is a serious complication after extraction of the mandibular third molar. It affects the function of the stomatognathic system and the quality of life of patients.

The significance of assessment of the relationship between nerve and canal is evident in the fact that the horizontal and vertical positions of the mandibular canal and corresponding third molars can serve as a key anatomic factor of IAN injury. Thus, a 3D assessment using CBCT aids in thorough pre-operative evaluation contributing to optimal risk assessment to predict IAN



injury.<sup>5</sup> Previous reports have emphasized that CBCT may serve as a surrogate “gold standard” method for validation of bony separation between the roots of the third molar and the mandibular canal.<sup>3</sup> Although CBCT provides accurate details of the position of mandibular canal and the impacted tooth relationship, there are few reports indicating that CBCT may not lead to the reduction of nerve injury and other complications, but it was only more effective in predicting the risk of IAN injury.<sup>17,19-21</sup>

CBCT significantly contributes to improved surgical management and aids in avoiding surgical complications. Alternate options such as coronectomy can be indicated for teeth that are very close to the IAN, if surgery needs to be postponed or is not feasible.<sup>17</sup> In addition to the positional relationship of nerve and roots, significant findings such as loss of cortical integrity, implying possible paresthesia in the post-operative phase, can be outlined by the use of CBCT.<sup>21</sup> Thus, CBCT in addition to panoramic radiography will facilitate optimal risk assessment and appropriate treatment planning.<sup>22</sup>

## Conclusion

In this retrospective observational study, the position of IAN with respect to the impacted third molars was assessed. Mesioangular impactions were the most commonly observed type of impactions. And the canal course in the impacted third molar was buccal in majority of the cases. However, the present study had few limitations like being a retrospective observational study; therefore, there was no scope to assess the post-operative outcome of the prediction of nerve damage. For this reason, further studies with post-operative correlation and follow-up with a larger sample size are recommended to emphasize the importance of incorporating the detailed method of categorizing the relationship of IAN with impacted third molars during routine radiographic reporting.

## Conflict of Interests

Authors have no conflict of interests.

## Acknowledgments

The authors would like to thank Dr. Kriti Nikhil who assisted in statistical analysis.

## References

1. Shahidi S, Zamiri B, Bronoosh P. Comparison of panoramic radiography with cone beam CT in predicting the relationship of the mandibular third molar roots to the alveolar canal. *Imaging Sci Dent* 2013; 43(2): 105-9.
2. Juodzbals G, Daugela P. Mandibular third molar impaction: Review of literature and a proposal of a classification. *J Oral Maxillofac Res* 2013; 4(2): e1.
3. Matzen LH, Wenzel A. Efficacy of CBCT for assessment of impacted mandibular third molars: a review-based on a hierarchical model of evidence. *Dentomaxillofac Radiol* 2015; 44(1): 20140189.
4. Gu L, Zhu C, Chen K, Liu X, Tang Z. Anatomic study of the position of the mandibular canal and corresponding mandibular third molar on cone-beam computed tomography images. *Surg Radiol Anat* 2018; 40(6): 609-14.
5. Matzen LH, Schropp L, Spin-Neto R, Wenzel A. Use of cone beam computed tomography to assess significant imaging findings related to mandibular third molar impaction. *Oral Surg Oral Med Oral Pathol Oral Radiol* 2017; 124(5): 506-16.
6. Matzen LH, Schropp L, Spin-Neto R, Wenzel A. Radiographic signs of pathology determining removal of an impacted mandibular third molar assessed in a panoramic image or CBCT. *Dentomaxillofac Radiol* 2017; 46(1): 20160330.
7. Wang D, Lin T, Wang Y, Sun C, Yang L, Jiang H, et al. Radiographic features of anatomic relationship between impacted third molar and inferior alveolar canal on coronal CBCT images: risk factors for nerve injury after tooth extraction. *Arch Med Sci* 2018; 14(3): 532-40.
8. Shiratori K, Nakamori K, Ueda M, Sonoda T, Dehari H. Assessment of the shape of the inferior alveolar canal as a marker for increased risk of injury to the inferior alveolar nerve at third molar surgery: A prospective study. *J Oral Maxillofac Surg* 2013; 71(12): 2012-9.
9. Tachinami H, Tomihara K, Fujiwara K, Nakamori K, Noguchi M. Combined preoperative measurement of three inferior alveolar canal factors using computed tomography predicts the risk of inferior alveolar nerve injury during lower third molar extraction. *Int J Oral Maxillofac Surg* 2017; 46(11): 1479-83.
10. Maglione M, Costantinides F, Bazzocchi G. Classification of impacted mandibular third molars on cone-beam CT images. *J Clin Exp Dent* 2015; 7(2): e224-e231.

11. Selvi F, Dodson TB, Nattestad A, Robertson K, Tolstunov L. Factors that are associated with injury to the inferior alveolar nerve in high-risk patients after removal of third molars. *Br J Oral Maxillofac Surg* 2013; 51(8): 868-73.
12. Quirino de Almeida BR, Bezerra de Melo N, de Macedo B, I, Area Leao Lopes Araujo Arruda MJ, Meira BP. Association between impacted third molars and position of the mandibular canal: A morphological analysis using cone-beam computed tomography. *Br J Oral Maxillofac Surg* 2018; 56(10): 952-5.
13. Ge J, Zheng JW, Yang C, Qian WT. Variations in the buccal-lingual alveolar bone thickness of impacted mandibular third molar: our classification and treatment perspectives. *Sci Rep* 2016; 6: 16375.
14. Byahatti S. The relationship of the inferior alveolar nerve canal with the roots of impacted mandibular third molars in a group of the South Indian population. *Indian J Oral Sci* 2015; 6(3): 108-12.
15. Chaurasia A, Giri S, Patil R. Evaluation of impacted 3<sup>rd</sup> molars in Indian ethnicity on panoramic radiograph-a cross sectional study. *J Oral Med Oral Surg Oral Pathol Oral Radiol* 2016; 2(4): 203-9.
16. Guerrero ME, Nackaerts O, Beinsberger J, Horner K, Schoenaers J, Jacobs R. Inferior alveolar nerve sensory disturbance after impacted mandibular third molar evaluation using cone beam computed tomography and panoramic radiography: A pilot study. *J Oral Maxillofac Surg* 2012; 70(10): 2264-70.
17. Xu GZ, Yang C, Fan XD, Yu CQ, Cai XY, Wang Y, et al. Anatomic relationship between impacted third mandibular molar and the mandibular canal as the risk factor of inferior alveolar nerve injury. *Br J Oral Maxillofac Surg* 2013; 51(8): e215-e219.
18. Kim JW, Cha IH, Kim SJ, Kim MR. Which risk factors are associated with neurosensory deficits of inferior alveolar nerve after mandibular third molar extraction? *J Oral Maxillofac Surg* 2012; 70(11): 2508-14.
19. Ghaeminia H, Gerlach NL, Hoppenreijns TJ, Kicken M, Dings JP, Borstlap WA, et al. Clinical relevance of cone beam computed tomography in mandibular third molar removal: A multicentre, randomised, controlled trial. *J Craniomaxillofac Surg* 2015; 43(10): 2158-67.
20. Guerrero ME, Botetano R, Beltran J, Horner K, Jacobs R. Can preoperative imaging help to predict postoperative outcome after wisdom tooth removal? A randomized controlled trial using panoramic radiography versus cone-beam CT. *Clin Oral Investig* 2014; 18(1): 335-42.
21. Park W, Choi JW, Kim JY, Kim BC, Kim HJ, Lee SH. Cortical integrity of the inferior alveolar canal as a predictor of paresthesia after third-molar extraction. *J Am Dent Assoc* 2010; 141(3): 271-8.
22. Ghaeminia H, Meijer GJ, Soehardi A, Borstlap WA, Mulder J, Vrijmen OJ, et al. The use of cone beam CT for the removal of wisdom teeth changes the surgical approach compared with panoramic radiography: a pilot study. *Int J Oral Maxillofac Surg* 2011; 40(8): 834-9.